








Different Functional and Microstructural Changes Depending on Duration of Mild Cognitive Impairment in Parkinson Disease

 N.-Y. Shin,  Y.S. Shin,  P.H. Lee,  U. Yoon,  S. Han,  D.J. Kim, and  S.-K. Lee



ABSTRACT

BACKGROUND AND PURPOSE: The higher cortical burden of Lewy body and Alzheimer disease–type pathology has been reported to be associated with a faster onset of cognitive impairment of Parkinson disease. So far, there has been a few studies only about the changes of gray matter volume depending on duration of cognitive impairment in Parkinson disease. Therefore, our aim was to evaluate the different patterns of structural and functional changes in Parkinson disease with mild cognitive impairment according to the duration of parkinsonism before mild cognitive impairment.

MATERIALS AND METHODS: Fifty-nine patients with Parkinson disease with mild cognitive impairment were classified into 2 groups on the basis of shorter (<1 year, $n = 16$) and longer (≥ 1 year, $n = 43$) durations of parkinsonism before mild cognitive impairment. Fifteen drug-naïve patients with de novo Parkinson disease with intact cognition were included for comparison. Cortical thickness, Tract-Based Spatial Statistics, and seed-based resting-state functional connectivity analyses were performed. Age, sex, years of education, age at onset of parkinsonism, and levodopa-equivalent dose were included as covariates.

RESULTS: The group with shorter duration of parkinsonism before mild cognitive impairment showed decreased fractional anisotropy and increased mean and radial diffusivity values in the frontal areas compared with the group with longer duration of parkinsonism before mild cognitive impairment (corrected $P < .05$). The group with shorter duration of parkinsonism before mild cognitive impairment showed decreased resting-state functional connectivity in the default mode network area when the left or right posterior cingulate was used as a seed, and in the dorsolateral prefrontal areas when the left or right caudate was used as a seed (corrected $P < .05$). The group with longer duration of parkinsonism before mild cognitive impairment showed decreased resting-state functional connectivity mainly in the medial prefrontal cortex when the left or right posterior cingulate was used as a seed, and in the parieto-occipital areas when the left or right caudate was used as a seed (corrected $P < .05$). No differences in cortical thickness were found in all group contrasts.

CONCLUSIONS: Resting-state functional connectivity and WM alterations might be useful imaging biomarkers for identifying changes in patients with Parkinson disease with mild cognitive impairment according to the duration of parkinsonism before mild cognitive impairment. The functional and microstructural substrates may topographically differ depending on the rate of cognitive decline in these patients.

ABBREVIATIONS: AD = Alzheimer disease; DMN = default mode network; MCI = mild cognitive impairment; PCC = posterior cingulate cortex; PD = Parkinson disease; PD-IC = PD with intact cognition; PD-MCI = PD with mild cognitive impairment; PD-MCI-LD = PD-MCI with ≥ 1 year of parkinsonism prior to MCI; PD-MCI-SD = PD-MCI with <1 year of parkinsonism prior to MCI; RSFC = resting-state functional connectivity

Parkinson disease (PD) has been considered, until recently, primarily a motor disorder. It is now recognized that a substantial portion of patients with PD have measurable cognitive deficits ranging from mild cognitive impairment (PD-


MCI) to dementia.^{1,2} Although the exact pathologic substrates for cognitive impairment in PD are still under debate, limbic and cortical Lewy body– and Alzheimer disease (AD)–type pathology have been suggested as the main contributors to

Received July 20, 2015; accepted after revision October 26.

From the Department of Radiology (N.-Y.S.), Ewha Womans University School of Medicine, Seoul, Korea; Department of Psychology (Y.S.S., S.H.), Yonsei University, Seoul, Korea; Departments of Neurology (P.H.L.) and Radiology (N.-Y.S., D.J.K., S.-K.L.), Yonsei University College of Medicine, Seoul, Korea; and Department of Biomedical Engineering (U.Y.), College of Health and Medical Science, Catholic University of Daegu, Gyeongsan-si, South Korea.

Please address correspondence to Seung-Koo Lee, MD, PhD, Department of Radiology, Yonsei University College of Medicine, Integrated Neurocognitive Functional Imaging Center, Yonsei University, Seoul, Korea, 50–1 Yonsei-ro, Seodaemun-gu, Seoul 120–752, Korea; e-mail: slee@yuhs.ac

 Indicates article with supplemental on-line appendix and tables.

 Indicates article with supplemental on-line photos.

<http://dx.doi.org/10.3174/ajnr.A4626>

PD-MCI³⁻⁶ as well as PD with dementia.⁷⁻⁹ In terms of the rate of cognitive decline, a higher burden of these cortical pathologies^{9,10} has been reported associated with a faster onset of cognitive impairment in PD.

In contrast to pathologic studies, imaging studies are noninvasive and useful for discovering biomarkers in living humans. However, only a few structural imaging studies^{11,12} have been conducted thus far to define anatomic candidates influencing the rate of cognitive decline in PD. These studies have revealed atrophy of the posterior cingulate cortex (PCC)¹¹ and inferior parietal and orbitofrontal areas¹² in patients with PD with shorter durations of parkinsonism before dementia and MCI, compared with those with longer durations of parkinsonism. These regions show considerable overlap with the default mode network (DMN), which is well-known to be disrupted in patients with AD.¹³ Some authors have suggested that impairment of axonal transport causes accumulation of axonally transported substances followed by cortical Lewy body formation.^{14,15} In other words, alterations in WM, such as swelling and degeneration of the axonal projections, may precede cortical atrophy. Functional imaging is a more sensitive biomarker that detects earlier stages of disease than that seen structurally for both AD and PD.¹⁶⁻¹⁸ However, there has been no study on the changes in WM integrity or resting-state functional connectivity (RSFC) according to the duration of parkinsonism before cognitive impairment in PD.

Therefore, we aimed to determine the structural and functional changes in patients with PD-MCI according to the duration of parkinsonism before MCI. During the resting-state fMRI analysis, we particularly focused on the DMN, which is highly associated with cognitive dysfunction in patients with AD¹³ and other neurodegenerative disorders.¹⁹ Furthermore, we also analyzed the corticostriatal loop, which is considered one of the primary areas of cognitive dysfunction in patients with PD.¹⁷

MATERIALS AND METHODS

Subjects

This retrospective study was approved by the Yosei University Health System institutional review board, and a waiver of informed consent was obtained. The patients were selected from a prospectively collected single-institution movement disorders and dementia outpatient clinic data base. From August 2011 to February 2014, consecutive patients with PD who underwent both MR imaging and neuropsychological tests within a 2-month interval were recruited. PD was diagnosed according to the clinical diagnostic criteria of the United Kingdom Parkinson's Disease Society Brain Bank.²⁰

Assessment of parkinsonian motor symptoms was performed by using the Unified Parkinson's Disease Rating Scale, Part III. Total medication dosages for PD were calculated in levodopa equivalents.²¹ The self-rating Beck Depression Inventory was used to assess depressive symptoms in patients with PD.²² Patients with focal brain lesions, diffuse white matter hyperintensities outside the normal range, or multiple lacunar infarcts in the basal ganglia on MR imaging were excluded. Patients with other neurodegenerative diseases and medical comorbidities that might account for cognitive dysfunction were also excluded. Only patients who displayed decreased dopamine transporter uptake in

the posterior putamen on a [¹⁸F] N-3-fluoropropyl-2- β -carboxymethoxy-3- β -(4-iodophenyl) nortropane (FP-CIT) PET scan were included in this study, to ensure clinical diagnostic accuracy.

Information about memory problems or other subjective cognitive deficits was gathered by interviews with the patients or caregivers. The cognitive status diagnosis in patients with PD was assigned by consensus among 2 neurologists and 1 neuropsychologist on the basis of a neuropsychological battery and the physician-administered neurologic examination. The Seoul Neuropsychological Screening Battery was used to determine the cognitive status,²³ and its details are described in On-line Appendix 1. According to the diagnostic criteria recommended by the Movement Disorder Society Task Force,²⁴ PD-MCI was diagnosed when results of at least 2 tests for each of the attention, executive, memory, and visuospatial function domains, except for the language domain (level 2), or in 5 domains (level 1) were abnormal. Patients with PD-MCI were split into 2 groups by disease duration before MCI: PD-MCI with <1 year of parkinsonism before MCI (PD-MCI-SD) and PD-MCI with ≥ 1 year of parkinsonism before MCI (PD-MCI-LD). Drug-naïve patients with de novo PD with intact cognition (PD-IC) were also included as control group.

Image Acquisition

All scans were acquired by using a 3T scanner (Achieva; Philips Healthcare, Best, the Netherlands) with a 32-channel head coil. Head motion was minimized with restraining foam pads provided by the manufacturer.

Structural Image Acquisition. We used a 3D-T1-turbo field echo sequence with the following parameters: axial acquisition with FOV = 220 mm; voxel size = $0.98 \times 0.98 \times 1.2$ mm³; TE = 4.6 ms; TR = 9.6 ms; flip angle = 8°; section gap = 0 mm; and total acquisition time = 5 minutes 29.3 seconds.

DTI Acquisition. A single-shot EPI acquisition was performed with the following parameters: FOV = 220 mm; voxel size = $1.72 \times 1.72 \times 2$ mm³; TE = ~ 70 ms; TR = ~ 8000 ms; flip angle = 90°; section gap = 0 mm; NEX = 1; b factor = 600 s/mm²; noncardiac gating; and 70 axial sections. We acquired diffusion-weighted images from 32 noncollinear, noncoplanar directions with a baseline image without diffusion-weighting. Total acquisition time was 5 minutes 44.6 seconds.

Resting-State fMRI Acquisition. We used a T2*-weighted single-shot EPI sequence. For each subject, 165 axial volume scans were obtained with the following parameters: FOV = 220 mm²; voxel size = $2.75 \times 2.75 \times 4.5$ mm³; TE = 30 ms; TR = 2000 ms; and section number = 31 (interleaved). During each scan, subjects were instructed to rest and keep their eyes closed without moving, sleeping, or thinking about anything in particular for 5 minutes 38 seconds.

Image Analysis

Cortical Thickness Analysis. Automated anatomic pipeline image processing steps were applied for cortical thickness measurement by using T1-weighted images. Details for measuring cortical

thickness are described in On-line Appendix 2. The localized regional differences of cortical thickness among groups were analyzed by applying ANCOVA, with age, sex, years of education, age at onset of parkinsonism, and levodopa-equivalent dose entered as covariates.

Tract-Based Spatial Statistics Analysis. DTI data preprocessing was performed by using the FMRIB Software Library (FSL; <http://www.fmrib.ox.ac.uk/fsl>) program. Details for Tract-Based Spatial Statistics (<http://fsl.fmrib.ox.ac.uk/fsl/fslwiki/TBSS>) analysis are described in On-line Appendix 3. In the ANCOVA analysis, age, sex, years of education, age at onset of parkinsonism, and levodopa-equivalent dose were included as covariates.

Seed-Based RSFC Analysis. Data were first preprocessed according to the Data Processing Assistant for Resting-State fMRI toolbox (<http://www.restfmri.net>) preprocessing pipeline implemented in Matlab (MathWorks, Natick, Massachusetts). Images were corrected for section timing, realigned, normalized by using the EPI template provided by SPM8 software (<http://www.fil.ion.ucl.ac.uk/spm/software/spm8>), and smoothed by using a 4-mm full width at half maximum Gaussian kernel. After normalization, to remove long-term drift and irrelevant oscillations in the signal, we detrended and bandpass filtered (0.01–0.08 Hz) data. Nuisance covariates, including head-motion parameters, global mean signals, WM signals, and CSF signals, were regressed out.

To perform seed-based analysis, an Automated Anatomical Labeling template (<http://www.gin.cnrs.fr/AAL>) defined 90 seed ROIs. Among them, 4 ROI seeds were selected to study the association of cognition and resting-state functional networks in patients with PD. First, the bilateral PCC seeds were chosen to investigate alterations within the DMN. Second, the bilateral caudate seeds, which are known to be key subcortical structures in the cognitive corticostriatal loop, were also selected. RSFC from each ROI seed was estimated and used to configure a statistical map. Two sample *t* tests were performed on each pair of the group's statistical images by using the SPM8 toolbox. The assumptions of unequal variance and independence among all groups were made on *t* tests. To exclude possible confounding factors, we covariated out age, sex, years of education, age at onset of parkinsonism, and levodopa-equivalent doses in the statistical test after normalization across 2 groups of interest by using the *z* score function in Matlab. The threshold for statistical analysis was set to corrected $P < .05$ by using the Monte Carlo simulations with custom software implemented in Matlab.²⁵

Correlation Analysis

Two-tailed Pearson correlation analyses were performed to assess the relationship between the duration of parkinsonism before MCI and RSFCs, which showed remarkable differences between the PD-MCI-SD and PD-MCI-LD groups (left hippocampus and left medial frontal gyrus with the left PCC seed and left middle frontal gyrus with the left caudate seed). For each ROI, *z* values were extracted from correlation maps with a 4-mm radius sphere centered at the peak. Then, the correlation coefficients between the *z* values and the patients' duration of parkinsonism before MCI were computed.

Statistical Analysis

Clinical characteristics and neuropsychological data were compared among the 3 groups. The Kolmogorov-Smirnov test was used to determine whether the data were normally distributed. Accordingly, data that had normal distribution are presented as means \pm SDs, and quantitative variables were compared by using an ANOVA. Otherwise, for comparing quantitative values, data are presented as medians with ranges and the Kruskal-Wallis test was used. Qualitative data were analyzed by using the χ^2 test or Fisher exact test when appropriate. Post hoc analysis was also performed by using a Bonferroni-corrected Student *t* test, Mann-Whitney *U* test, χ^2 test, or Fisher exact test when appropriate with correction for multiple comparisons. Statistical analyses were performed by using SPSS, Version 19.0 (IBM, Armonk, New York), and 2-tailed $P < .05$ was considered significant.

RESULTS

Demographic and Clinical Characteristics

Among 239 patients with PD who underwent both MR imaging and neuropsychological tests, 59 patients with PD-MCI who met the inclusion criteria were analyzed in this study. Fifteen drug-naïve patients with de novo PD with intact cognition were also included for comparison. The demographic and clinical data of the patients are summarized in Table 1. The median duration of parkinsonism in the PD-MCI-SD group ($n = 16$) was 5 months and it was 25 months in the PD-MCI-LD group ($n = 43$). Patients in the PD-MCI-SD group had significantly older age at onset than those in the PD-MCI-LD group (68.5 ± 7.3 years versus 61.6 ± 9.0 years; $P = .016$). No significant differences were found in neuropsychological data between the 2 PD-MCI groups (On-line Table 1).

Group Comparisons of Cortical Thickness

No difference in cortical thickness was found among all groups.

Group Comparisons of WM Alterations

Compared with the de novo PD-IC group, the PD-MCI-SD group showed increased mean diffusivity in the bilateral anterior and superior corona radiata, genu and body of corpus callosum, right cingulum, and right superior longitudinal fasciculus and increased radial diffusivity in the right anterior and superior corona radiata, genu and body of the corpus callosum, right cingulum, and right superior longitudinal fasciculus (On-line Fig 1). The PD-MCI-LD group did not show significant WM alterations compared with the PD-IC group. In direct comparison between the PD-MCI-SD and PD-MCI-LD groups, the PD-MCI-SD group showed significantly decreased fractional anisotropy values in the right superior longitudinal fasciculus and corticospinal tract compared with the PD-MCI-LD group. More extensive changes were found in mean diffusivity and radial diffusivity values, showing a significant increase in the bilateral anterior and superior corona radiata, bilateral superior longitudinal fasciculus, genu and body of corpus callosum, right cingulum, and anterior and posterior limbs of the right internal capsule in the PD-MCI-SD group (Fig 1). No significant difference was found in axial diffusivity among groups.

Table 1: Demographic and clinical characteristics of the patients^a

	De Novo PD-IC (n = 15)	PD-MCI-SD (n = 16)	PD-MCI-LD (n = 43)	P Value ^b	Post Hoc Analysis		
					P1 ^c	P2 ^d	P3 ^e
Age (yr)	65.7 ± 6.4	69.1 ± 7.2	64.9 ± 8.9	.221	—	—	—
Age at onset (yr)	64.9 ± 6.5	68.5 ± 7.3	61.6 ± 9.0	.017	.672	.555	.016
Male (No.) (%)	6 (40.0)	8 (50.0)	17 (39.5)	.604	—	—	—
Education duration (yr)	10.6 ± 4.7	8.8 ± 4.2	9.5 ± 5.2	.598	—	—	—
Parkinsonism duration (mo) (median) (range)	11 (2–18)	5 (1–11)	25 (12–120)	<.001	.015	<.001	<.001
UPDRS III	19.1 ± 8.3	25.4 ± 8.8	25.6 ± 11.2	.100	—	—	—
K-MMSE	28.6 ± 1.2	26.3 ± 1.5	26.9 ± 2.1	.002	.003	.009	.899
Levodopa-equivalent dose (mg) (median) (range)	0.0 (0.0–0.0)	0.0 (0.0–360.0)	25.0 (0.0–1050.0)	.008	.030	.006	1.000
BDI	11.7 ± 7.6	14.1 ± 8.7	14.8 ± 10.2	.543	—	—	—
Interval between MRI scan and NP test (day) (median) (range)	0 (0–34)	0 (0–49)	0 (0–50)	.266	—	—	—

Note:—BDI indicates Beck Depression Inventory; K-MMSE, the Korean version of the Mini-Mental State Examination; NP test, neuropsychological test; UPDRS III, Unified Parkinson's Disease Rating Scale, Part III; —, not significant.

^a Unless otherwise indicated, data are means.

^b P values for comparison among 3 groups.

^c P values for comparison between de novo PD-IC and PD-MCI-SD groups.

^d P values for comparison between de novo PD-IC and PD-MCI-LD groups.

^e P values comparison between PD-MCI-SD and PD-MCI-LD groups.

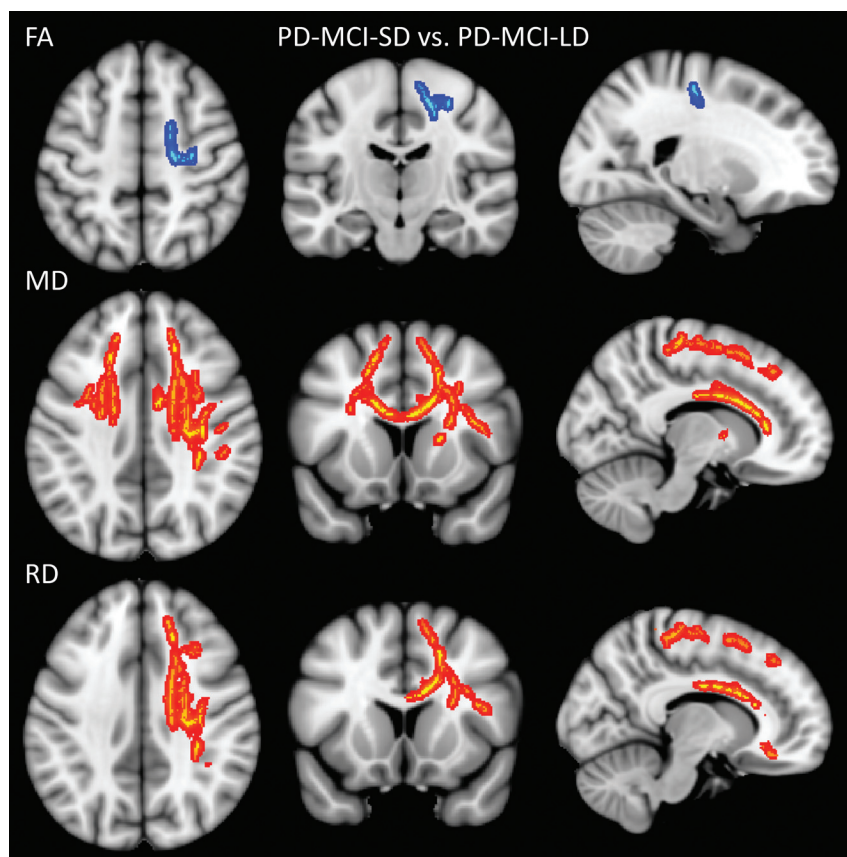


FIG 1. Tract-Based Spatial Statistics analysis in the PD-MCI groups. Warm colors indicate increased DTI values, and cool colors indicate decreased DTI values in the PD-MCI-SD group compared with PD-MCI-LD group ($P < .05$, family-wise error–corrected). Images are oriented according to neurological convention (right is right).

Group Comparisons of RSFC by Using the PCC Seeds

Compared with the de novo PD-IC group, the PD-MCI-SD group showed decreased RSFC in the parahippocampal gyrus, dorsolateral prefrontal areas, temporal areas, and precuneus, whereas increased RSFC was seen in the inferior frontal areas, primary motor area, and

occipital areas. The PD-MCI-LD group showed decreased RSFC in the medial frontal areas and middle cingulate cortex, while increased RSFC was seen mainly in the parietal and occipital areas, compared with the de novo PD-IC group. In direct comparison between the PD-MCI-SD and PD-MCI-LD groups, the PD-MCI-SD group showed decreased RSFC in the hippocampus, parietal areas, cuneus, and thalamus; on the contrary, the PD-MCI-LD group showed decreased RSFC in the medial and inferior frontal areas, primary motor area, cingulate cortex, inferior temporal area, and insula (Fig 2A, -B; On-line Fig 2 and On-line Table 2).

Group Comparison of RSFC by Using the Caudate Seeds

Compared with the de novo PD-IC group, the PD-MCI-SD group exhibited decreased RSFC in the putamen, temporal areas, precuneus, and insula and increased RSFC in the primary sensory motor areas. On the other hand, the PD-MCI-LD group showed decreased RSFC in the occipital area and thalamus and increased RSFC in the frontal areas, including the primary and supplementary motor areas, hippocampus/parahippocampal gyrus and other temporal areas, and the supramarginal gyri. In direct comparison between the PD-

MCI-SD and PD-MCI-LD groups, the PD-MCI-SD group showed decreased RSFC in the putamen, globus pallidus, frontal and temporal areas, middle cingulate cortex, and insula, while the PD-MCI-LD group showed decreased RSFC mainly in the pari-

etal and occipital areas (Fig 2C, -D; On-line Fig 3 and On-line Table 3).

Correlation Analysis

The RSFC between the left caudate and left middle frontal gyrus (Montreal Neurological Institute coordinates $[-36, 33, 33]$) was significantly correlated with the duration of parkinsonism before MCI ($r = 0.292, P = .025$). RSFCs between the left PCC and left hippocampus (Montreal Neurological Institute coordinates $[-24, -36, -3]$) and the left PCC and left medial frontal gyrus (Montreal Neurological Institute coordinates $[-6, 54, 24]$) were not significantly correlated with the duration of parkinsonism before MCI (Fig 3).

DISCUSSION

The present study examined the different patterns of structural and functional changes in patients with PD-MCI according to the

duration of parkinsonism before MCI. First, the PD-MCI-SD group showed decreased frontostriatal RSFC, which was correlated with the duration of parkinsonism before MCI, and impaired frontal WM integrity compared with the PD-MCI-LD group. Second, the pattern of RSFC was topographically different between the 2 groups. The PD-MCI-SD group showed decreased RSFC in the DMN, while the PD-MCI-LD group showed decreased RSFC in the medial frontal areas with the PCC seeds. Third, no difference was found in cortical thickness among all group contrasts.

As mentioned earlier, the PD-MCI-SD group showed not only decreased frontostriatal RSFC but also decreased fractional anisotropy values and increased mean diffusivity and radial diffusivity values in the frontal WM compared with the PD-MCI-LD group. These functional and microstructural differences might be attributable to both striatal^{26,27} and frontal^{28,29} pathologies. Recently, some pathologic studies have suggested striatal β -amyloid²⁶ or α -synuclein²⁷ deposits as a primary substrate for subcortical dementia in PD. Moreover, a higher degree of amyloid deposits in the striatum was found in patients with dementia with Lewy bodies than in those with PD with dementia, suggesting the possible role of amyloid deposition in the acceleration of cognitive decline in α -synuclein-related cognitive disorders.³⁰ A previous imaging study also showed atrophy of the caudate nucleus and frontal cortex in patients with PD-MCI who subsequently converted to PD with dementia compared with those without conversion to PD with dementia.³¹ Furthermore, our results showed that frontostriatal RSFC had significant correlation with the duration of parkinsonism before MCI. In other words, patients with more disrupted RSFC among these areas had MCI with a shorter interval after the onset of motor symptoms. Although the effort to determine which substrate has a primary role in accelerat-

ion, some pathologic studies have suggested striatal β -amyloid²⁶ or α -synuclein²⁷ deposits as a primary substrate for subcortical dementia in PD. Moreover, a higher degree of amyloid deposits in the striatum was found in patients with dementia with Lewy bodies than in those with PD with dementia, suggesting the possible role of amyloid deposition in the acceleration of cognitive decline in α -synuclein-related cognitive disorders.³⁰ A previous imaging study also showed atrophy of the caudate nucleus and frontal cortex in patients with PD-MCI who subsequently converted to PD with dementia compared with those without conversion to PD with dementia.³¹ Furthermore, our results showed that frontostriatal RSFC had significant correlation with the duration of parkinsonism before MCI. In other words, patients with more disrupted RSFC among these areas had MCI with a shorter interval after the onset of motor symptoms. Although the effort to determine which substrate has a primary role in accelerat-

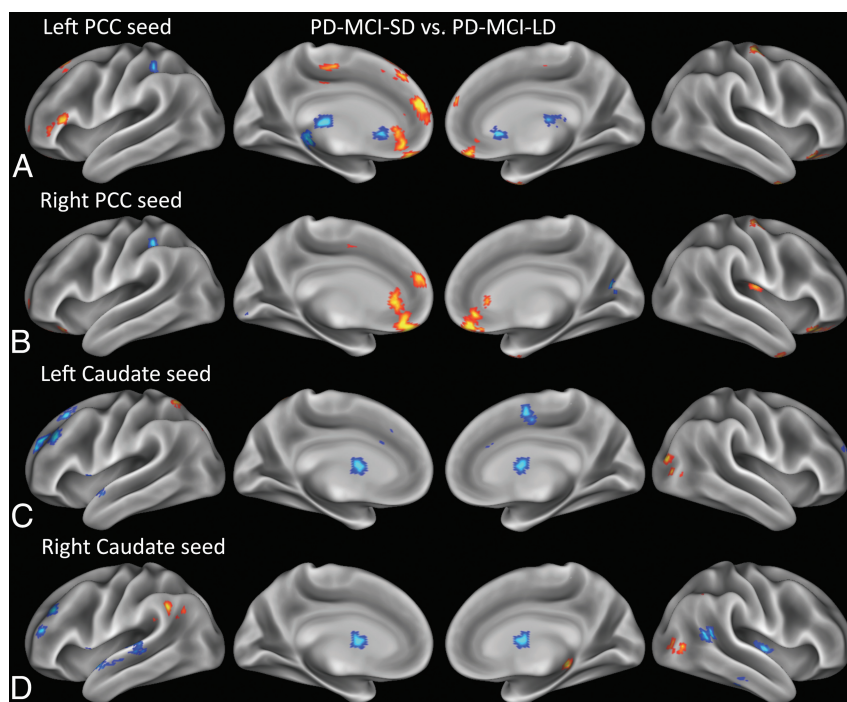


FIG 2. RSFC analysis in the PD-MCI groups by using the PCC and caudate as a seed. Warm colors indicate increased connectivity, and cool colors indicate decreased connectivity in PD-MCI-SD group compared with PD-MCI-LD group. All demonstrated clusters are significant at a $P < .05$ level, with correction for multiple comparisons.

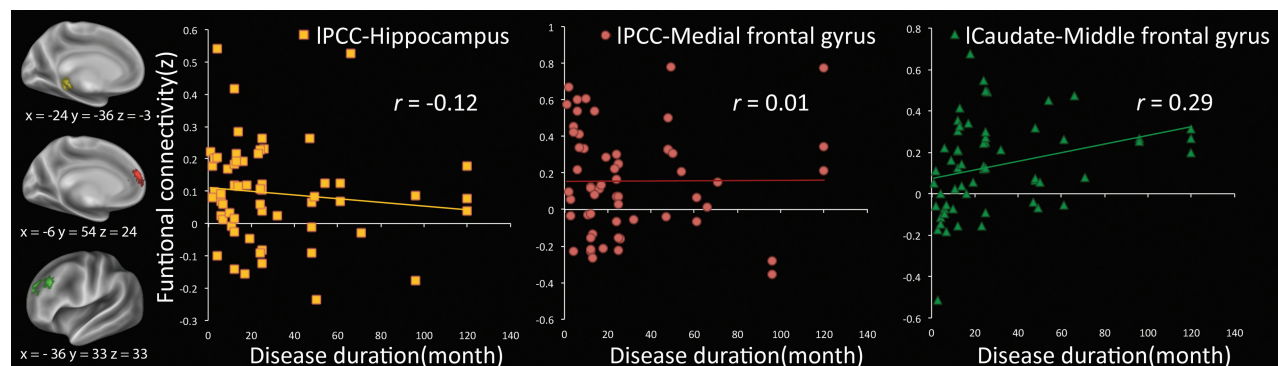


FIG 3. Correlation graph between the duration of parkinsonism before MCI and each ROI. The duration of parkinsonism before MCI is significantly correlated with only RSFC between the left caudate and left middle frontal gyrus ($P = .025$).

ing cognitive decline should be continued, functional or microstructural alterations in the frontostriatal circuit may be a useful imaging biomarker for more rapid cognitive decline in patients with PD-MCI.

Compared with the PD-MCI-LD group, the PD-MCI-SD group also showed decreased RSFC in the DMN, including the hippocampus and inferior parietal lobule when PCC was used as a seed. Our results are in line with those in previous reports. According to previous imaging studies, patients with a shorter duration of parkinsonism before cognitive impairment in PD with dementia and PD-MCI had decreased GM volume in the PCC¹¹ and in the inferior parietal and orbitofrontal areas,¹² respectively. These areas substantially overlap with the DMN, which is susceptible to decline in patients with AD.¹³ Moreover, a recent study reported AD pattern atrophy involving the hippocampus and temporal-parietal cortex as a predictor for 2-year future cognitive decline in PD,³² suggesting that an AD imaging pattern is an important predictor for more rapid cognitive decline. Decreased RSFC between the PCC and the hippocampus has been observed in early AD and MCI.^{13,33} In AD, tauopathy involving the medial temporal lobe, including the hippocampus, is considered a possible cause of the decreased connectivity.³⁴ Although this finding is less clear in PD,^{17,18} pathologic evidence has suggested that the degree of Lewy body,³⁵ Lewy neurite,³⁶ β -amyloid, or neurofibrillary tangle deposit³⁷ in the entorhinal cortex or hippocampus is associated with cognitive dysfunction.

Most interesting, the PD-MCI-LD group had decreased RSFC primarily in the medial frontal areas and cingulate when using the PCC seeds compared with the PD-MCI-SD group. Braak et al³⁸ reported sequential topographic extension of Lewy neurite and Lewy body deposits in PD, with these areas showing substantial overlap with the affected areas in stage 5, which is the first stage of neocortical involvement. One pathologic study³⁹ found that among the patients who remained without dementia for a long time, the patients who had longer disease durations until death had more extensive Lewy body deposits, consistent with the PD stage of Braak et al. These patients had no or a low AD pathology burden. Therefore, decreased RSFC in these areas might be associated with cortical PD pathology accumulated for longer disease durations in the PD-MCI-LD group relative to the PD-MCI-SD group. In addition, when the caudate seeds were used, the PD-MCI-LD group showed decreased RSFC in mainly parieto-occipital areas compared with the PD-MCI-SD group. These areas, which are cognitive- and action-specific domains, have functional connection with the caudate tail, while the caudate head has a stronger functional connection with the prefrontal areas.⁴⁰ Further pathologic study is warranted to define different topographic areas involved within the caudate between the 2 groups.

Our study has several limitations. First, our cohort was not pathologically proved to have PD. Instead, we used dopamine transporter imaging to reduce the possibility of misdiagnosis. Second, the diagnosis of PD-MCI in this study did not fully satisfy the level 2 criteria of the Movement Disorder Society Task Force guideline for some patients.²⁴ Therefore, the possibility of patients with false-positive diagnoses in the PD-MCI group cannot be excluded. Third, although only the patients who underwent both MR imaging and neuropsychological tests within a 2-month

interval were included, there were 1- to 50-day intervals in 21 patients in our cohort. While the cognitive state might not change during this relatively short period, this range of intervals might have affected the results. Fourth, because we used seed-based RSFC analysis with only PCC and caudate seeds, the role of the remaining areas for cognitive decline rates could have been missed in patients with PD. Moreover, recent studies have suggested that dorsal attention⁴¹ and frontoparietal networks^{41,42} are associated with cognitive dysfunction in patients with PD-MCI. Therefore, future study with a data-driven approach of the whole brain should be conducted to consolidate our results and find other relevant networks influencing the cognitive decline rate in these patients. Fifth, it is still unclear what RSFC and DTI values exactly represent in the brain. Therefore, caution is needed to interpret our results until underlying pathologic evidence is elucidated. Finally, this study is a cross-sectional one, so our findings cannot be applied to predict the rate of development of cognitive decline. A prospective study with regular follow-up with comprehensive neuropsychological testing is warranted. However, we compared each PD-MCI group with the de novo PD-IC group, and areas showing decreased RSFC in these comparisons were similar to those in direct comparison between the 2 PD-MCI groups. Therefore, we hope that our results can provide an a priori hypothesis for future studies to define imaging biomarkers for the cognitive decline rate in drug-naïve patients with de novo PD-IC.

CONCLUSIONS

Our results indicate that changes in RSFC and WM integrity in PD-MCI according to the duration of parkinsonism before MCI are more sensitive imaging biomarkers than cortical thickness. We also found topographically different functional and microstructural substrates corresponding to the timing of MCI in PD-MCI.

REFERENCES

1. Emre M, Aarsland D, Brown R, et al. **Clinical diagnostic criteria for dementia associated with Parkinson's disease.** *Mov Disord* 2007;22:1689–707; quiz 837 [Medline](#)
2. Litvan I, Aarsland D, Adler CH, et al. **MDS Task Force on mild cognitive impairment in Parkinson's disease: critical review of PD-MCI.** *Mov Disord* 2011;26:1814–24 [CrossRef Medline](#)
3. Adler CH, Caviness JN, Sabbagh MN, et al. **Heterogeneous neuropathological findings in Parkinson's disease with mild cognitive impairment.** *Acta Neuropathol* 2010;120:827–28 [CrossRef Medline](#)
4. Jellinger KA. **Neuropathology in Parkinson's disease with mild cognitive impairment.** *Acta Neuropathol* 2010;120:829–30; author reply 31 [CrossRef Medline](#)
5. Alves G, Brønnick K, Aarsland D, et al. **CSF amyloid-beta and tau proteins, and cognitive performance, in early and untreated Parkinson's disease: the Norwegian ParkWest study.** *J Neurol Neurosurg Psychiatry* 2010;81:1080–86 [CrossRef Medline](#)
6. Montine TJ, Shi M, Quinn JF, et al. **CSF β (42) and tau in Parkinson's disease with cognitive impairment.** *Mov Disord* 2010;25:2682–85 [CrossRef Medline](#)
7. Compta Y, Pereira JB, Rios J, et al. **Combined dementia-risk biomarkers in Parkinson's disease: a prospective longitudinal study.** *Parkinsonism Relat Disord* 2013;19:717–24 [CrossRef Medline](#)
8. Compta Y, Ibarretxe-Bilbao N, Pereira JB, et al. **Grey matter volume correlates of cerebrospinal markers of Alzheimer-pathology in Parkinson's disease and related dementia.** *Parkinsonism Relat Disord* 2012;18:941–47 [CrossRef Medline](#)

9. Compta Y, Parkkinen L, O'Sullivan SS, et al. **Lewy- and Alzheimer-type pathologies in Parkinson's disease dementia: which is more important?** *Brain* 2011;134:1493–505 CrossRef Medline
10. Ballard C, Ziabreva I, Perry R, et al. **Differences in neuropathologic characteristics across the Lewy body dementia spectrum.** *Neurology* 2006;67:1931–34 CrossRef Medline
11. Song SK, Lee JE, Park HJ, et al. **The pattern of cortical atrophy in patients with Parkinson's disease according to cognitive status.** *Mov Disord* 2011;26:289–96 CrossRef Medline
12. Lee JE, Cho KH, Kim M, et al. **The pattern of cortical atrophy in Parkinson's disease with mild cognitive impairment according to the timing of cognitive dysfunction.** *J Neurol* 2012;259:469–73 CrossRef Medline
13. Greicius MD, Srivastava G, Reiss AL, et al. **Default-mode network activity distinguishes Alzheimer's disease from healthy aging: evidence from functional MRI.** *Proc Natl Acad Sci U S A* 2004;101:4637–42 CrossRef Medline
14. Katsuse O, Iseki E, Marui W, et al. **Developmental stages of cortical Lewy bodies and their relation to axonal transport blockage in brains of patients with dementia with Lewy bodies.** *J Neurol Sci* 2003;211:29–35 CrossRef Medline
15. Bellucci A, Zaltieri M, Navarria L, et al. **From alpha-synuclein to synaptic dysfunctions: new insights into the pathophysiology of Parkinson's disease.** *Brain Res* 2012;1476:183–202 CrossRef Medline
16. Frisoni GB, Fox NC, Jack CR Jr, et al. **The clinical use of structural MRI in Alzheimer disease.** *Nat Rev Neurol* 2010;6:67–77 CrossRef Medline
17. Seibert TM, Murphy EA, Kaestner EJ, et al. **Interregional correlations in Parkinson disease and Parkinson-related dementia with resting functional MR imaging.** *Radiology* 2012;263:226–34 CrossRef Medline
18. Tessitore A, Esposito F, Vitale C, et al. **Default-mode network connectivity in cognitively unimpaired patients with Parkinson disease.** *Neurology* 2012;79:2226–32 CrossRef Medline
19. Fox MD, Greicius M. **Clinical applications of resting state functional connectivity.** *Front Syst Neurosci* 2010;4:19 CrossRef Medline
20. Hughes AJ, Daniel SE, Kilford L, et al. **Accuracy of clinical diagnosis of idiopathic Parkinson's disease: a clinico-pathological study of 100 cases.** *J Neurol Neurosurg Psychiatry* 1992;55:181–84 CrossRef Medline
21. Tomlinson CL, Stowe R, Patel S, et al. **Systematic review of levodopa dose equivalency reporting in Parkinson's disease.** *Mov Disord* 2010;25:2649–53 CrossRef Medline
22. Beck AT, Ward CH, Mendelson M, et al. **An inventory for measuring depression.** *Arch Gen Psychiatry* 1961;4:561–71 CrossRef Medline
23. Kang Y, Na DL. *Seoul Neuropsychological Screening Battery*. Incheon: Human Brain Research & Consulting Co; 2003
24. Litvan I, Goldman JG, Troster AL, et al. **Diagnostic criteria for mild cognitive impairment in Parkinson's disease: Movement Disorder Society Task Force guidelines.** *Mov Disord* 2012;27:349–56 CrossRef Medline
25. Slotnick SD, Moo LR, Segal JB, et al. **Distinct prefrontal cortex activity associated with item memory and source memory for visual shapes.** *Brain Res Cogn Brain Res* 2003;17:75–82 CrossRef Medline
26. Kalaitzakis ME, Graeber MB, Gentleman SM, et al. **Striatal beta-amyloid deposition in Parkinson disease with dementia.** *J Neuropathol Exp Neurol* 2008;67:155–61 CrossRef Medline
27. Tsuboi Y, Uchikado H, Dickson DW. **Neuropathology of Parkinson's disease dementia and dementia with Lewy bodies with reference to striatal pathology.** *Parkinsonism Relat Disord* 2007;13(suppl 3):S221–24 CrossRef Medline
28. Mattila PM, Rinne JO, Helenius H, et al. **Alpha-synuclein-immunoreactive cortical Lewy bodies are associated with cognitive impairment in Parkinson's disease.** *Acta Neuropathol* 2000;100:285–90 CrossRef Medline
29. Mattila PM, R  ytt   M, L  nnberg P, et al. **Choline acetyltransferase activity and striatal dopamine receptors in Parkinson's disease in relation to cognitive impairment.** *Acta Neuropathol* 2001;102:160–66 Medline
30. Jellinger KA, Attems J. **Does striatal pathology distinguish Parkinson disease with dementia and dementia with Lewy bodies?** *Acta Neuropathol* 2006;112:253–60 Medline
31. Lee JE, Cho KH, Song SK, et al. **Exploratory analysis of neuropsychological and neuroanatomical correlates of progressive mild cognitive impairment in Parkinson's disease.** *J Neurol Neurosurg Psychiatry* 2014;85:7–16 CrossRef Medline
32. Weintraub D, Dietz N, Duda JE, et al. **Alzheimer's disease pattern of brain atrophy predicts cognitive decline in Parkinson's disease.** *Brain* 2012;135:170–80 CrossRef Medline
33. Zhou Y, Dougherty JH Jr, Hubner KF, et al. **Abnormal connectivity in the posterior cingulate and hippocampus in early Alzheimer's disease and mild cognitive impairment.** *Alzheimers Dement* 2008;4:265–70 CrossRef Medline
34. Smith AD. **Imaging the progression of Alzheimer pathology through the brain.** *Proc Natl Acad Sci USA* 2002;99:4135–37 Medline
35. K  vari E, Gold G, Herrmann FR, et al. **Lewy body densities in the entorhinal and anterior cingulate cortex predict cognitive deficits in Parkinson's disease.** *Acta Neuropathol* 2003;106:83–88 Medline
36. Churchyard A, Lees AJ. **The relationship between dementia and direct involvement of the hippocampus and amygdala in Parkinson's disease.** *Neurology* 1997;49:1570–76 Medline
37. Kalaitzakis ME, Christian LM, Moran LB, et al. **Dementia and visual hallucinations associated with limbic pathology in Parkinson's disease.** *Parkinsonism Relat Disord* 2009;15:196–204 CrossRef Medline
38. Braak H, Del Tredici K, R  b U, et al. **Staging of brain pathology related to sporadic Parkinson's disease.** *Neurobiol Aging* 2003;24:197–211 Medline
39. Halliday G, Hely M, Reid W, et al. **The progression of pathology in longitudinally followed patients with Parkinson's disease.** *Acta Neuropathol* 2008;115:409–15 CrossRef Medline
40. Robinson JL, Laird AR, Glahn DC, et al. **The functional connectivity of the human caudate: an application of meta-analytic connectivity modeling with behavioral filtering.** *Neuroimage* 2012;60:117–29 CrossRef Medline
41. Baggio HC, Segura B, Sala-Ll  nch R, et al. **Cognitive impairment and resting-state network connectivity in Parkinson's disease.** *Hum Brain Mapp* 2015;36:199–212 CrossRef Medline
42. Amboni M, Tessitore A, Esposito F, et al. **Resting-state functional connectivity associated with mild cognitive impairment in Parkinson's disease.** *J Neurol* 2015;262:425–34 CrossRef Medline